



PRESENTING CLINICAL SIGNS

DATE History: Grade 3/6 murmur. Peritoneal effusion – 2000 ml modified transudate removed.

4/20/22 **ECHOCARDIOGRAPHIC FINDINGS**
2D, M-mode, and Doppler study.

PERFORMED BY: Left atrial size is normal. The mitral valve leaflets are mildly thickened, and a mild jet of eccentric mitral regurgitation is present. Left ventricular dimensions are normal. Left ventricular systolic function is hyperdynamic. The aorta and aortic valve are normal. Right atrial and right ventricular dimensions are normal. The tricuspid valve leaflets are mildly thickened, and a mild jet of tricuspid regurgitation is present. TR velocity does not suggest the presence of pulmonary hypertension. The pulmonary artery and pulmonic valve are normal. No pericardial effusion or cardiac masses are seen.

Loetitia Saint-Jacques, RVT

INTERPRETED BY

Keith Blass, DVM, MS, DACVIM (Cardiology)

LA – 47.4 mm
LVIDd – 44.4 mm
LVIDs – 22.1 mm
FS – 50.2%
RA – 33.1 mm
LVOT – 0.89 m/s
RVOT – 2.00 m/s
TR – 2.74 m/s

PATIENT

Maggie Franc

SPECIES **ASSESSMENT/RECOMMENDATIONS**

Canine

Degenerative mitral and tricuspid valve disease

BREED

Labrador Retriever

This examination demonstrates mild regurgitation of blood across Maggie's mitral and tricuspid valves resulting from degenerative valve disease. The hemodynamic effects of each of the regurgitations also appear to be mild, as Maggie does not have secondary dilation of any of her cardiac chambers, and her ventricular systolic function is well-preserved. As such, Maggie's valvular diseases appear to be well-compensated, and it does not appear that her ascites is cardiogenic in origin.

SEX

No therapy appears to be indicated at this stage of Maggie's valvular diseases.

FS

A recheck echocardiogram is recommended in 6 months to monitor for disease progression.

AGE

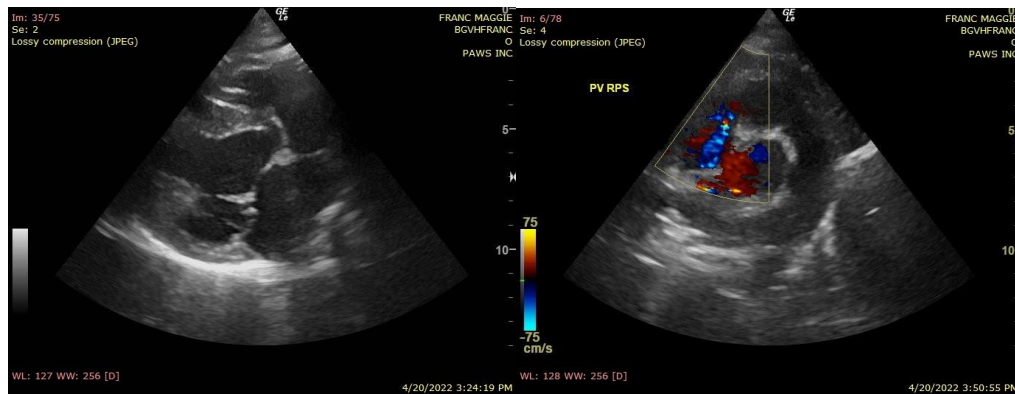
11 y

WEIGHT

73 lb

HOSPITAL NAME

Brighton Greens VH



REFERRING VET

Dr. Janeway



DATE

4/20/22

The information and recommendations provided are based on the images presented by the referring veterinarian. No evaluation can be communicated regarding pathology that was not visible in the image/video clips provided.

Thank you for this referral. If the clinical or image interpretation does not parallel your findings or if I can be of any further assistance please contact me.

PERFORMED BY:

Loetitia Saint-Jacques, RVT

Keith Blass, DVM, MS, DACVIM (Cardiology)
KeithBlass@gmail.com
631-804-5754

INTERPRETED BY

Keith Blass, DVM,
MS, DACVIM
(Cardiology)

PATIENT

Maggie Franc

SPECIES

Canine

BREED

Labrador Retriever

SEX

FS

AGE

11 y

WEIGHT

73 lb

HOSPITAL NAME

Brighton Greens VH

REFERRING VET

Dr. Janeway